



Current therapy

Laser hair removal

David J. Goldberg, MD

Laser Research, Department of Dermatology; Mount Sinai School of Medicine, 5 East 98th St., New York, NY 10029, USA

Long-term hair removal requires that a laser or light source damage one or more growth centers of hair. To do so, an appropriate target or chromophore must be identified. The major hair growth center has always been thought to be the hair matrix. As has now been described, however, new hairs may evolve from the dermal papilla, follicular matrix, or the bulge. Although the pluripotential growth sites of the arrector pili-associated bulge are only 1 to 1.5 mm below the skin surface, the other growth sites are often as deep as 3 to 7 mm in the skin. Because of the skin depth of these sites, significant energies must be applied for effective hair removal. Not only must each follicle be damaged, however, but the surrounding tissue, especially the epidermis, must be protected from damage. By doing so, adverse sequelae, such as scarring and permanent pigmentary changes, may be lessened. Melanin, the only endogenous chromophore in the hair follicle of pigmented hair, can be targeted effectively by lasers and light sources throughout the visible light spectrum. The longer melanin-absorbing wavelengths, seen with current lasers and light sources, are preferred because of their reduced scattering in the dermis and consequent greater depth of penetration.

The pluripotential cells of the bulge, dermal papilla, and hair matrix must be treated in the anagen cycle for effective hair removal. If the damage is not permanent during this cycle, follicles move into the telogen stage as they fall out. All of the follicles may become synchronized after the first laser treatment. The hair follicles then return to the anagen phase during the natural hair cycle. This cycle varies depending on the anatomic location. It is shortest on the

face and longer on the body, varying between several weeks to several months.

Selective photothermolysis describes the use of selected wavelengths to destroy particular targets in the skin. In tandem with the principle of selective photothermolysis is the concept of thermal relaxation time [1,2]. Thermal relaxation time is used to describe the limitation of thermal damage when a desired target absorbs a particular wavelength in an amount of time that is equal or less than that target's thermal relaxation time. With the right combination of wavelength, energy, and pulse duration, it is possible to target the hair follicle precisely without causing injury to the surrounding structures. One way to achieve greater injury to the hair follicle is by increasing the pulse duration of the laser exposure. The thermal relaxation time for hair follicles that are 200 to 300 μm in diameter is approximately 40 to 100 millisecond. If pulse duration were the only factor, then the ideal laser pulse duration should lie between the thermal relaxation time for epidermis, which is approximately 3 to 10 millisecond, and the thermal relaxation time for hair follicles. There are other factors, however, to consider. If a laser or light source delivers its energy through a large beam, an increase in skin penetration occurs. Greater depth of penetration provides a greater chance of reaching hair growth centers.

In human skin, about 15% to 20% of incident light at 700 nm penetrates to a depth of 3 mm. By using a large spot size, scattering of light in the dermis is lessened, leading to greater depth of penetration. In addition, whenever a melanin-absorbing laser or light source is used for hair removal, competing epidermal melanin must be protected from damage. This is usually accomplished by cooling the skin surface.

Currently popular cooling techniques include contact and cryogen cooling. Cold gel cooling, used exten-

Bruce H. Thiers, MD, Consulting Editor.

sively in the past, does not seem to be as consistent in its cooling ability.

Laser and light sources currently cleared by the Food and Drug Administration

Historically, there have been three somewhat different methods of using the concept of selective photothermolysis for the removal of hair. In the first either a laser or nonlaser light is used selectively target hair follicles. Here, the light is absorbed by a normal component of the follicular apparatus, melanin. In the third, now rarely used technique an exogenous chromophore applied to the hair was used years to absorb laser energy. The currently used wave-lengths for laser or light source hair removal are follows:

Ruby 694
Alexandrite 755
Diode 810
QS Nd:YAG 1064
Millisecond Nd:YAG 1064
Flashlamp 590-1100

Normal-mode ruby laser

Normal-mode millisecond ruby lasers produce 694-nm red light. This 694-nm laser light is well absorbed by melanin-containing hair. In the first published study evaluating the use of a ruby laser on human hair, Grossman et al [3] used a 270-microsecond pulsed ruby laser. The laser contained a contact cooling device that was designed to maximize delivery of deeper portions of the hair follicle while minimizing epidermal damage. This contact device contained a sapphire lens that was cooled to 4°C. The energy was delivered through a 6-mm spot size.

In the study, 13 human volunteers (12 men and 1 woman) were treated. All had Fitzpatrick skin phenotype III; all had brown or black hair. Treated areas from the back or thigh. Both shaved and epilated treated. The treated sites were evaluated fluences of 30, 40, and 60 J/cm². Hair counts determined 1, 3, and 6 months after laser treatment. Hair regrowth was defined as the percentage of terminal hairs present after treatment as compared with number before treatment. Immediately after treatment all sites became erythematous and edematous. There was rare purpura, epidermal whitening, or epidermal ablation. In evaluating the 1-, 3-, and 6-month results, the authors noted a statistically

significant growth delay at 1 and 3 months for all used fluences. At 6 months there was significantly less hair only at the 60 J/cm² shaved sites. Hyperpigmentation, present in three subjects, had cleared by the 6-month follow-up visit. Two subjects had transient hypopigmentation; no scarring was noted. The authors found that the presence of a hair shaft was not absolutely necessary for temporary hair removal. This effect resulted from the ample melanin contained in both the follicular epithelium and papilla. At 6 months, two, however, there was significant hair loss only at shaven to sites treated with the highest fluences. This suggests that the presence of a hair shaft actually enhances selective photothermolysis. Of the 13 subjects in the aforementioned study, 7 were followed up to 2 years after laser exposure. At 1 year and 2 years after treatment, four of the seven still had obvious hair loss as confined to the laser-treated sites and three had complete or nearly complete hair regrowth. In all seven participants, there was no significant change in terminal hair counts 6 months, 1 year, and 2 years after laser exposure. The fact that hair counts were unchanged 6 months after laser treatment suggests that 6-month follow-up may be sufficient to determine final results of laser hair removal.

This study further evaluated what seemed to be two distinct laser hair removal responses: temporary growth delay and permanent hair loss. Temporary growth delay seems to be caused by laser damage induction of the telogen phase. Permanent hair loss seems to be associated with miniaturization of hair follicles.

Anderson et al [4] in a 10-site multicenter study evaluated hair removal efficacy in 183 patients (30 men and 153 women) treated up to six treatments during the course of 1 year. All body sites were represented, and skin types I to V were included. The laser was a 694-nm, 3-millisecond ruby laser. Subjects were treated with the highest fluence tolerated, with a range of 10 to 60 J/cm². All were evaluated at baseline and 6 months after the final treatment. Re-treatments were undertaken at 6- to 12-week intervals depending on degree of hair regrowth. Of the 183 initially treated subjects, 80% sites were treated with a 7-mm spot size with fluences between 20 and 60 J/cm². Twenty percent were treated with a 10-mm spot size with fluences between 10 and 24 J/cm². The mean average number of treatments was 4.5. Nineteen percent of the treated subjects had 100% hair loss in the treatment area, regardless of the number of treatments, body sites, skin type, or hair color. Only 2% had less than 25% hair loss or total regrowth. The mean treatment fluence for subjects with 100% hair loss at the 6-month

follow-up was 32 J/cm² (range, 20 to 40 J/cm²). After a single treatment, 67% of subjects showed greater than 50% hair loss in the treated area. After multiple treatments, the percentage of subjects with greater than 50% hair loss increased to 90%. Most subjects had greater than 75% hair loss at 6 months following the final treatment. After a single treatment, most subjects showed either no change in color or texture of hairs. By the final 6-month follow-up visit, however, more than 90% of subjects showed finer hair and greater than 80% had lighter hair. The greatest response was noted in the axilla and bikini region, whereas the thighs and upper lip showed the poorest response. No scarring or textural changes were noted, although 6% of treated individuals were reported to have hyperpigmentation at 6 months. The incidence of hypopigmentation was 3%. Histologic evaluation showed miniaturization of treated hair follicles.

Although the ruby laser was the first universally accepted successful laser hair removal system (Figs. 1 and 2), it is no longer the most widely used. Some of the ruby lasers were very slow in their delivery of laser pulses making the system somewhat impractical for the treatment of large anatomic areas. Ruby lasers tend to produce greater quantities of heat than most other hair removal lasers. Other systems, described later, although not necessarily more effective, have become more popular than ruby lasers.

Normal-mode alexandrite laser

Finkel et al [5] were among the first group to evaluate the efficacy of the 755-nm alexandrite laser removing unwanted hair. They treated 126 patients (men and 116 women) with a 2-millisecond alexandrite laser. Among the 116 female patients, 77 had facial hair, 15 had bikini and leg hair, 4 had axillae hair,

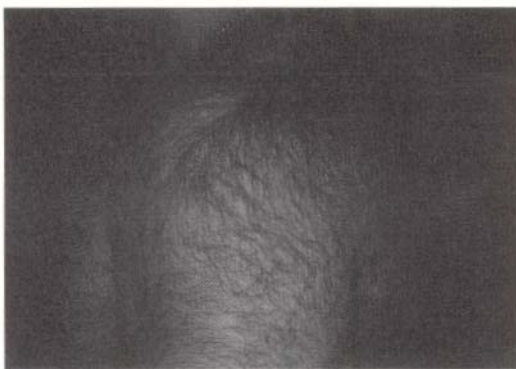

Fig. 1. Unwanted hair before treatment with a 694-nm ruby laser. Results were obtained with the 20-millisecond pulse duration ruby laser.

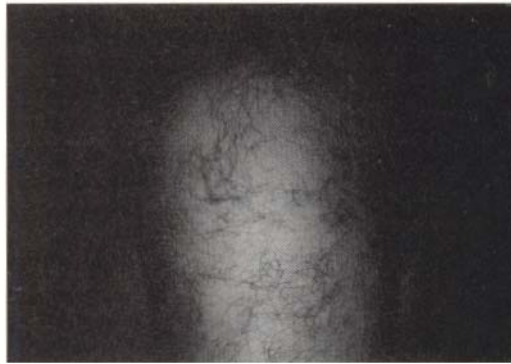


Fig. 2. Four months after one treatment with a ruby laser. Some hair loss noted. More sessions are required.

10 had areolar hair, and 10 had abdominal hair. The 10 male patients had backs or chests treated. The study was undertaken over a 15-month period.

All subjects were treated with a 2-millisecond alexandrite laser at 20 to 40 J/cm² (average of 25 J/cm²). Cooling of the epidermis was accomplished with a then popular cooling gel. The total number of treatments varied between three and five sessions. Treatment intervals varied between 1 and 2.5 months. The authors noted light erythema in 10% of treated patients. The erythema lasted up to several days. Superficial burns and blistering were noted in 6% of patients. Healing occurred within 10 days. Transient hypopigmentation was noted in 6% of individuals. Hypopigmentation lasted up to 3 months. The average hair loss after treatment was 45%. The numbers did vary, however, in different anatomic areas. As expected, there was progressive improvement with each laser hair removal session. The average amount of hair present 3 months after the final treatment was markedly less than that seen after the first session. Eighty eight percent hair loss was reported by the end of the study. The results varied from 95% of hairs removed from the sideburns; 90% of hairs removed from the upper lip, bikini, legs, axillae, and periareolar breast area; 85% of hairs removed from the chin and male backs and chest areas; and 75% of hairs removed from the abdomen. The authors found that treatment with this particular 2-millisecond alexandrite laser was extremely fast because of the five pulse per second repetition rate.

Narukar et al [6] evaluated both a 20-millisecond and 5-millisecond pulse duration alexandrite laser in skin phenotypes IV to V. All individuals were treated with less than 20 J/cm². In this study, better duration. Longer pulse duration laser hair removal

systems may be more beneficial in individuals with darker complexions.

These findings must be contrasted with the observations of Nanni and Alster [7]. They also evaluated the hair removal efficacy of one laser treatment session using different alexandrite laser pulse durations. In their study, they examined the hair removal clinical efficacy and side effect profile of a 5-, 10-, or 20-millisecond duration pulsed alexandrite laser.

Thirty-six subjects (9 men and 27 women; age to 68 years; average 31 years) were evaluated. Only terminal hairs were treated. Hair was treated from the upper lip, back, or lower extremities. Subjects had Fitzpatrick skin phototypes I to V. Fluences of 15 to 20 J/cm² (average of 18 J/cm²) were delivered. Comparisons were made between the 5-, 10-, and 20-millisecond pulse durations. An immediate erythematous skin response was an observed end point in the laser-irradiated sites. All laser-treated areas displayed a significant delay in hair regrowth compared with a control area at 1 week and 1 and 3 months. No significant differences were seen in hair regrowth rates between the use of 5-, 10-, and 20-millisecond pulse durations. An average of 66% hair reduction was recorded at the 1-month follow-up, 27% average hair reduction was observed at the 3-month follow-up, and only a 4% hair decrease remained at the 6-month follow-up visit. The authors noted that after the one treatment used in this study, there was on average no significant reduction in hair growth by the 6-month follow-up. Complications were limited to immediate posttreatment erythema in 97% of treated sites; minimal intraoperative treatment pain in 85%; transient hyperpigmentation in 3%; and mild blistering in less than 1% (one case) of treated subjects. Of note, although hyperpigmentation was observed at all pulse durations in certain individuals, it was generally of less severity and resolved more rapidly in the 20-millisecond pulse duration treated areas. These findings were consistent with those seen by Narkuar et al [6]. Average duration of hyperpigmentation was 6 weeks.

The authors noted that, in contrast to the findings et al [6], all pulse durations resulted in equivalent hair removal. What was not determined in was whether a slightly shorter pulse duration might be more effective in thinner hair, whereas correspondingly longer pulse duration might more be more effective in thicker, larger hairs.

It should be noted that higher fluences (up to 40 J/cm²) are often necessary when the ruby laser is used to achieve long-term hair reduction. Because the alexandrite laser penetrates deeper into the dermis compared with the ruby laser, such high flu-

ences may not be required. Nevertheless, the fluences used in this study were conservative and may have led to a reduced rate of efficacy. Higher fluences may be required to maximize potential efficacy.

The authors compared the effect of pulse duration and multiple treatments on alexandrite laser hair removal efficacy [8]. Fourteen subjects (3 men and 11 women) between the ages of 19 and 51 were studied. Treatment sites included the chin, neck, back, bikini, and lower leg; Fitzpatrick skin phenorange 18 types were I to III. All subjects had black or brown uated. terminal hairs.

An alexandrite laser with a pulse duration of 2 millisecond, energy fluence of 25 J/cm², 7-mm spot size was compared with an alexandrite laser with a pulse duration of 10 millisecond, energy fluence of 25 J/cm², and a 7-mm spot size. Consecutive treatment and evaluations occurred at 2- to 3-month intervals for a total of three treatment visits. Posttreatment complications, such as erythema, pigmentary changes, and scars, were evaluated. Two-millisecond and 10-millisecond laser treatment results were compared, side by side, for a given anatomic site. Manual terminal hair counts were performed at baseline and compared with similar evaluations at 6 months following the final treatment. The average percentage of hair reduction was 33.1% for the 2-millisecond pulse duration and 33.9% for the 10-millisecond pulse duration alexandrite laser. There was a slightly greater, albeit statistically insignificant, loss of thicker hairs (such as those seen on the back of men) with the 10-millisecond alexandrite laser. The most common posttreatment complication was perifollicular erythema. This developed immediately after treatment and resolved within 24 to 48 hours. No cutaneous pigmentary changes or scarring was noted 6 months after the final treatment.

This study was unique, in that it was the first to compare two different pulse durations after multiple treatments. It should be noted that that the results showed a greater degree of improvement than that seen in the studies by Nanni and Alster [7]. This is probably caused by the greater number of treatment received by the author's patients. Currently, a 3-millisecond alexandrite laser with up to an 18-mm spot size and cryogen cooling of the skin is one of the most popular laser hair removal systems (Figs. 3 and 4).

Diode laser

An 810-nm diode laser is also one of the more popular available hair removal systems. Dierickx et al when [9] evaluated the effectiveness and safety of a pulsed

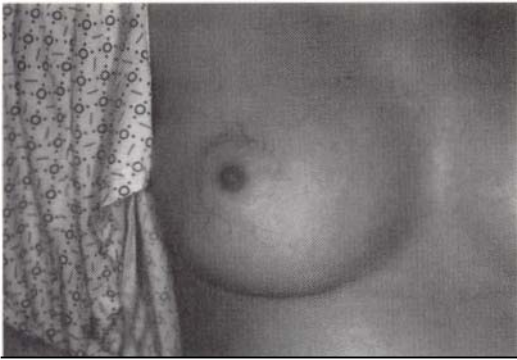

Fig. 3. Unwanted hair before treatment with a 755-nm millisecond alexandrite laser.

diode laser in the permanent reduction of unwanted hair. Ninety-five subjects were evaluated. Most had Fitzpatrick II to III skin phenotypes (ranging from II and dark hair. Subjects were treated and I examined at baseline, 1, 3, 6, 9, and 12 months after treatment. The objective of the study was not only to investigate effectiveness and safety of a pulsed diode laser in the permanent reduction of pigmented hair, also to study the fluence-response relationship. The authors also evaluated one versus two treatments. 810-nm diode laser delivered pulse durations from 5 to 20 millisecond and fluences from 15 to 40 J/cm². Laser energy was delivered over a 9x9 mm. The handpiece contained an actively cooled sapphire lens that, when pressed against the subject's skin slightly before and during each laser pulse, provides thermal protection for the epidermis.

Treatment results demonstrated two different effects on hair growth: hair growth delay and per-

manent hair reduction. A measurable growth delay was seen in all patients (100%) at all fluence-pulse width configurations tested; this growth delay was sustained for 1 to 3 months.

Clinically obvious long-term hair reduction usually required greater than or equal to 30 J/cm². After two treatments at 40 J/cm² with a 20-millisecond pulse duration, the average permanent hair reduction at the end of the study was 46%. Two treatments significantly increased hair reduction as compared with one treatment, with an apparently additive effect. At a fluence of 40 J/cm², the initial treatment removed approximately 30% of terminal hairs, and the second treatment given 1 month later removed an additional 25%.

Of note, hair regrowth stabilized at 6 months at all fluences; there was no further hair regrowth between 6, 9, and 12 months in this study. This stabilizing of hair regrowth or hair count is consistent with the clinically accepted growth cycle of many hair follicles. This has also been observed with other wavelength laser systems.

In addition to statistically significant hair reduction, treatment with the laser also showed reduction in hair diameter and reduction in color of regrowing but hairs. Regrowing mean hair diameter decreased by 19.9%. The hairs remaining after treatment were the lighter and thinner.

The typical expected posttreatment response of cm². perifollicular erythema and edema was noted. Approximately 20% of patients exhibited pigment changes, which resolved in 1 to 3 months. Most pigment changes were transient, but with darker skin types and higher fluences, some persistent pigment changes were noted. This laser continues to be a very popular hair removal system (Figs. 5 and 6).

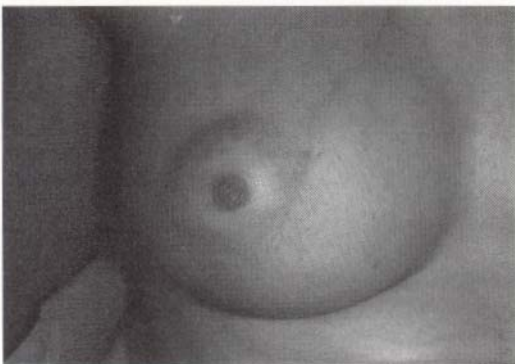

Fig. 4. Six months after four treatments with an alexandrite laser.

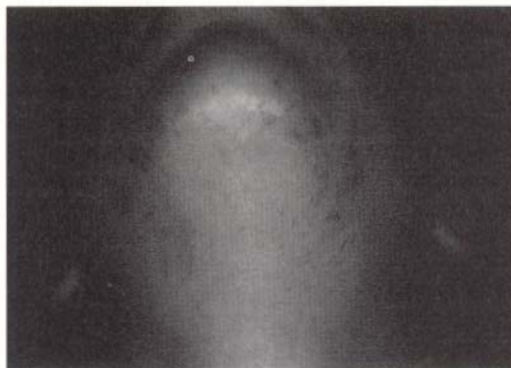

Fig. 5. Unwanted hair before treatment with an 810-nm millisecond diode laser.

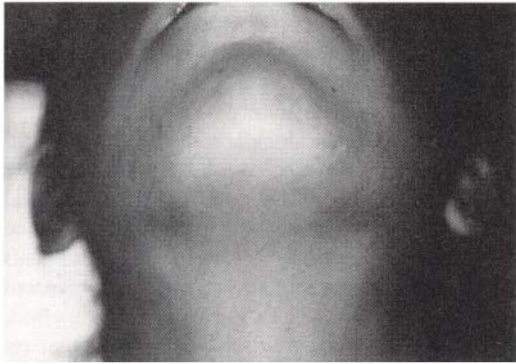


Fig. 6. Six months after four treatments with a diode laser.

Intense pulsed nonlaser light source

Gold et al [10] published the first significant series of patients treated with a nonlaser, broad-spectrum, multiwavelength light source used for hair removal. They evaluated hair removal efficacy in 31 subjects. Patients ranged in age from 14 to 74 years. Although a variety of anatomic sites were treated, the most common areas were the neck (27%); lip (22%); and chin (19%). Delivered fluences ranged between 34 and 55 J/cm². Energy was delivered in sequences of between two and five pulses, each pulse varying between 1.5 and 3.5 millisecond in length. Interpulse delay time varied between 20 and 50 millisecond. Seventy percent of subjects showed greater than 75% clearance.

The authors only followed patients for 12 weeks. could be no claim of long-term hair removal. In addition, patients were treated only one time. This has in subsequent studies. It is expected that the results improve after multiple treatments. Of note, the authors did not delineate which Fitzpatrick skin phenotypes were treated. It might be expected that the complication rate rises if darker skin types are treated.

This nonlaser hair removal device, although clearly effective, has dropped in popularity because of its longer learning curve than is seen with many other effective hair removal lasers.

Nd:YAG laser

One of the very first studied hair removal lasers was a short-pulsed nanosecond Q-switched Nd:YAG laser. The effect of this laser, it was at one time thought, could be potentiated with an exogenous laser-absorbing chromophore (carbon). The study was an initial pilot evaluation, using this technique 60 subjects of varying skin types and hair colors

[11]. Most treated sites were on the face. A proprietary suspension of 10 μ m carbon particles was applied to the skin and irradiated with 2 to 4 J/cm² of Q-switched Nd:YAG laser light (1064 nm, 10 Hz, 10 ns pulse duration, 7 mm spot size). Up to a 70% reduction in hair growth and a reduction of hair coarseness and hair lightening was noted 3 months after laser treatment. Local anesthesia was generally not necessary. No scarring or pigmentary changes were reported.

Unfortunately, a subsequent study of 12 patients determined that one treatment had no long-term benefit [7]. This study compared wax epilation and carbon suspension Q-switched Nd:YAG (2.6 J/cm², 7 - spot size) laser irradiation with and without prior

waxing. At 3 months follow-up there was 70% to 86% hair regrowth at all sites except for the wax epilation alone, which had 100% regrowth. By

6 months there was 100% regrowth in all sites (33). Switched Nd:YAG laser hair removal treatments at the current time seem to be only of historic interest. It seems that the very short nanosecond pulses delivered from such systems simply do not create enough thermal damage to promote long-term hair removal.

The author recently studied a millisecond Nd:YAG laser on 15 health adult volunteers, ranging in age from 28 to 69 years of age, with a total of 29 treated areas. All subjects had Fitzpatrick I to III skin phenotypes with brown or black hair [12]. Treatment, through a contact cooling device, was then undertaken using a millisecond 1064-nm Nd:YAG laser. Laser energy was delivered through a 2-mm diameter spot size, 30-millisecond pulse duration and fluence of 125 to 130 J/cm² for facial hair and 150 J/cm² for nonfacial hair. Hair reduction varied between 50% and 60% at 90 days. The perceived

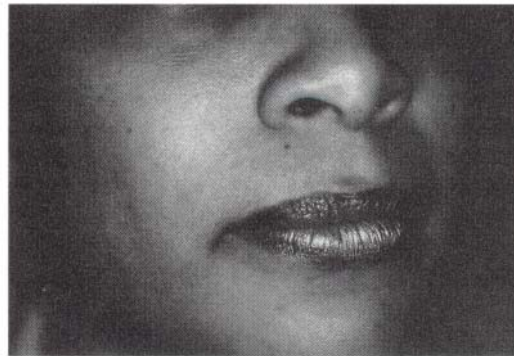


Fig. 7. Three months after two with an Nd:YAG laser. Note Fitzpatrick V, individual without pigmentary changes.

reduction of facial hair was greater than that of non-facial hair. No complications or adverse effects were reported at any of the follow-up examinations.

In a somewhat similar study, a millisecond Nd:YAG laser was evaluated using 15- to 30-millisecond pulse durations and fluences of 50 to 60 J/cm² (S. Kilmer, personal communication, 2000). Twenty-five subjects with 100 treatment sites were evaluated. Skin phenotypes I to V were evaluated; anatomic sites included the face, arms, legs, axilla, bikini, and back. Response was assessed 3 months after a single treatment. The median hair count reduction 3 months after a single treatment was 32% for treatment parameters of 60 J/cm² and 30 millisecond and 24% for the treatment parameters of 50 J/cm² and 15 millisecond.

The epidermal response 1 day following treatment included erythema, edema, and infrequent blistering. At the 3-month follow-up visit, minimal hyperpigmentation was noted in only 5 of 100 treated sites. No hypopigmentation was noted.

Because such cooled millisecond systems are less absorbed by epidermal melanin than all of the previously described systems, the Nd:YAG lasers now become very popular for the treatment of ethnic or tanned skin (Fig. 7).

Summary

Laser hair removal created controversy when it was first described over 5 years ago. It has now become an accepted modality for long-term hair reduction. It rivals electrolysis in the successful treatment of small hair-bearing areas. It surpasses any modality in the treatment of larger hair-bearing anatomic areas.

References

- [1] Anderson RR, Parrish JA. The optics of human skin. *J Invest Dermatol* 1981;77:13-7.
- [2] Anderson RR, Parrish JA. Selective photothermolysis: precise microsurgery by selective absorption of pulsed radiation. *Science* 1983;220:524.
- [3] Grossman MC, Dierickx C, Farinelli W, et al. Damage to hair follicles by normal-mode ruby laser pulses. *J Am Acad Dermatol* 1996;35:889-94.
- [4] Anderson R, Burns AJ, Garden J, Goldberg D, et al. Multicenter study of long-pulse ruby laser hair removal. *Lasers Surg Med* 1999;24(suppl 11):21.
- [5] Finkel B, Eliczri YD, Waldman A, et al. Pulsed alexandrite laser technology for non-invasive hair removal. *J Clin L Med Surg*. 1997;15:225.
- [6] Narukar V, Miller HM, Seltzer R. The safety and efficacy of the long pulse alexandrite laser for hair removal in various skin types. *Lasers Surg Med* 1998;18 (suppl 10):38.
- [7] Nanni CA, Alster TS. Laser-assisted hair removal: optimizing treatment parameters to improve clinical results [abstract]. *Lasers Surg Med* 1997;18(suppl 9):35.
- [8] Goldberg DJ, Akhmi R. Evaluation comparing multiple treatments with a 2-millisecond and 10-millisecond alexandrite laser for hair removal. *Lasers Surg Med* 1999;25:223-8.
- [9] Dierickx CC, Grossman MC, Farinelli BS, et al. Hair removal by pulsed infrared diode laser. *Lasers Surg Med* 1998;10:42.
- [10] Gold MH, Bell MW, Foster TD, et al. Long-term epilation using the EpiLight broad hand, intense pulsed light hair removal system. *Dermatol Surg*. 1997;23:909.
- [11] Goldberg DJ, Littler CK, Wheeland RM. Topical suspension assisted Q-switched Nd:YAG laser hair removal. *Dermatol Surg*. 1997;23:1006.
- [12] Goldberg DJ, Samady J. Evaluation of a long-pulse Q-switched Nd:YAG laser for hair removal. *Dermatol Surg* 2000;26:109-13.