

# Atrophic and a Mixed Pattern of Acne Scars Improved With a 1320-nm Nd:YAG Laser

ARLENE S. ROGACHEFSKY, MD,<sup>\*†</sup> MUSSARAT HUSSAIN, MD,\* AND DAVID J. GOLDBERG, MD<sup>\*†</sup>

*\*Skin Laser and Surgery Specialists of New York and New Jersey, Hackensack, New Jersey, and Mount Sinai School of Medicine, New York, New York*

**BACKGROUND.** Acne scar correction remains a challenge to the dermatologic surgeon. With nonablative laser resurfacing, this correction is imputed to dermal collagen remodeling and acne scar reorganization. Although atrophic acne scars tend to respond to laser treatment, the deeper ice pick and boxcar scars tend to be laser resistant.

**OBJECTIVE.** To investigate the treatment of atrophic and a mixed pattern of facial acne scars, we evaluated a 1320-nm Nd:YAG laser. Twelve subjects with atrophic facial acne scars ( $N = 6$ ) or a combination of atrophic and pitted, sclerotic, or boxcar scars ( $N = 6$ ) received three laser treatments. Physician

and patient acne scar ratings were performed at baseline and at 6 months after the last treatment. Acne scars were rated with a 10-point severity scale.

**RESULTS.** Mean acne scar improvement was 1.5 points on physician assessments ( $P = 0.002$ ) and 2.2 points on patient assessments ( $P = 0.01$ ). Acne scars were rated more severely by patients than by the physician at all intervals. There were no noted complications at 6 months. **CONCLUSION.** The 1320-nm Nd:YAG laser is a safe and effective nonablative modality for the improvement of atrophic and a mixed pattern of facial acne scars.

*STUDY FUNDING WAS IN PART BY COOLTOUCH LASERS, ROSEDALE, CA.*

ACNE SCARRING can take several clinical forms, including atrophic, saucerized, ice pick, and boxcar scars.<sup>1</sup> Histologically, these acne scars are associated with a loss of collagen.<sup>2</sup> Although the deeper ice pick and boxcar scars are resistant to laser treatment and respond best to punch excision, punch elevation, tissue augmentation, and fat transplantation,<sup>3</sup> atrophic scars generally respond to laser.<sup>4-12</sup>

Atrophic or saucerized scars, which appear as shallow, rolling scars wider than 4 to 5 mm, are the result of an inflammatory response to an initial lesion, which terminates in collagen destruction, dermal atrophy, and fibrosis. As the scar matures and contracts, the dermal nature of the scar produces a bound-down appearance. These scars are exaggerated with aging as facial skin starts to sag and hang on the inelastic scars.<sup>13</sup> This combination often influences patients, as they approach middle age, to seek corrective surgery for long-standing acne scars. Although laser resurfacing can improve the appearance of saucerized acne scarring, it is associated with an extended recovery and significant postoperative complications.<sup>14</sup>

Nonablative laser irradiation has been introduced as a safer modality for the correction of acne scars. This correction is attributed to stimulating neocolla

genesis to refill the residual defects.<sup>5,15</sup> Devices in the visible spectrum (532 nm,<sup>12</sup> 585 nm<sup>1,16</sup>) and in the midinfrared wavelengths (980 nm, 1,320 nm,<sup>15</sup> 1,450 nm,<sup>17</sup> 1,540 nm<sup>1</sup>) are being explored for the treatment of acne scars. The 1320-nm Nd:YAG laser, because of its poor melanin absorption, can be used in all skin types. Because this laser beam has an advantageous high scattering coefficient and nonspecific absorption by dermal water, it penetrates deeply into the papillary and midreticular dermis. Therefore, the 1320-nm Nd:YAG laser could potentially improve deeper acne scars.

The goal of this study was to evaluate a 1320-nm Nd:YAG laser with cryogen spray cooling for the treatment of atrophic and a mixed pattern of facial acne scars. Acne scars were assessed by a dermatologist and by the patients at baseline and at 6 months, and complications were noted.

## Methods

### Laser

A 1320-nm Nd:YAG laser (CoolTouch II; ICN Pharmaceuticals, Costa Mesa, CA) with a 10-mm spot size and a thermal sensor was used to deliver fluences of 13 to 22J/cm<sup>2</sup>. The laser's 50-ms macropulse consists of six 300- $\mu$ s train pulses.

Address correspondence and reprint requests to: David J. Goldberg, MD, Skin Laser and Surgery Specialists of New York and New Jersey, 20 Prospect Avenue, Suite 702, Hackensack, NJ 07601.

### Cooling System

Precooling (30 ms) or postcooling (30 ms) was applied with cryogen spray (tetrafluoroethane), which cooled the skin to approximately 0°C. After 30-ms of precooling, there was an interpulse delay of 10-ms before the laser pulse. Before 30-ms of postcooling, there was interpulse delay of 40-ms after the laser pulse.

### Patient Selection

Twelve subjects (10 female patients and 2 male patients) with atrophic facial acne scars ( $N = 6$ ) or a combination of atrophic and pitted, sclerotic, or boxcar facial acne scars ( $N = 6$ ) were enrolled in this study. The subjects had Fitzpatrick skin types 1-111 and a mean age of 50 (range of 35 to 59). Subjects were excluded for the presence of solely pitted acne scars or boxcar scars, pregnancy or lactation, predisposition for hypertrophic scars or keloids, a history of laser resurfacing or dermabrasion on the face in the previous year, or if immunocompromised.

### Protocol

Three laser treatments were performed, separated by 1-month intervals. At each treatment, the full face was irradiated with three consecutive laser passes. The first

and second passes delivered fluences of 16 to 22J/cm<sup>2</sup> in the precooling mode, and the third pass delivered fluences of 13 to 17J/cm<sup>2</sup> in the postcooling mode. The fluences for passes 1 and 2 were determined by achieving peak surface temperatures of 43°C to 46°C. The fluences for pass 3 were determined by measuring the subject's starting skin temperature and adjusting fluences according to the manufacturer's guidelines (above 35°C = 13 J/cm<sup>2</sup>; 33°C to 34°C = 15 J/cm<sup>2</sup>; 30°C to 32°C = 17J/cm<sup>2</sup>; below 30°C = prewarm patient).

Preprocedure anesthesia was not provided. No postexposure skin care was recommended except for antibiotic ointment application if blistering were to occur.

Photographs and physician and patient clinical evaluations were undertaken at baseline and at 6 months after the last treatment. Subjects were categorized at baseline into two groups: those having a predominance of atrophic scars (as defined by more than 90%) and those having atrophic scars in combination with other types of acne scars (including pitted, sclerotic, or boxcar scars). Acne scars were visually assessed and then independently rated by both a nontreating dermatologist and the treated subjects. Assessments were undertaken using a 10-point severity

rating scale: 1 = most imperceptible acne scars and 10 = most severe acne scars.' The scale defines mild acne scarring with a score of 1 to 3, moderate acne scarring as 4 to 6, and severe acne scarring as 7 to 10. Photographs, which were captured with a Nikon N80 35-mm Camera, using a Nikon Macro Speedlight Ring Flash SB-21 with a F Stop of 3.2, were always taken with the same settings. Complications at 6 months after the last treatment were to be noted.

### Statistics

Nonparametric rank tests were used because of the ordinal nature of the 10-point severity rating scale and the small sample size. The signed rank test was used for paired comparisons of before and after acne scar ratings performed by the physician and patient. The Mann-Whitney rank sum test was used to compare the scores of the atrophic scarred patients with those with a mixed pattern of scarring. A P value of less than 0.05 was considered significant; two-tailed P values are presented.

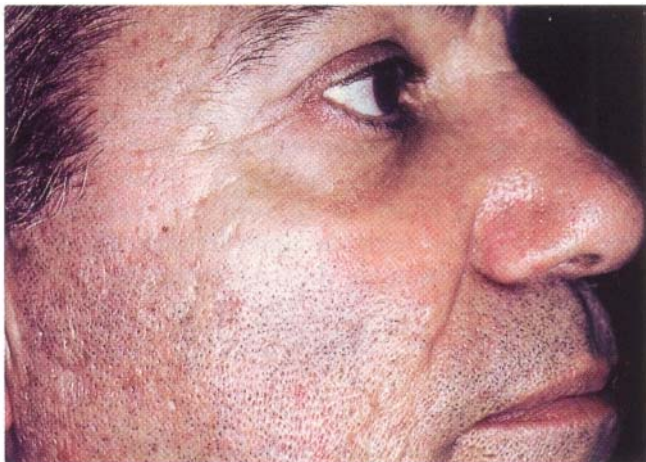### Results

Mean acne scar improvement on the 10-point severity scale was 1.5 points for physician assessment ( $P = 0.002$ ) and 2.2 points for patient assessment ( $P = 0.01$ ). For physician assessment, the mean acne scar baseline rating of 4.9 (range of 3 to 7) dropped to 3.4 (range of 2 to 6) at 6 months, resulting in a mean acne scar improvement of 1.5 points. For subject assessment, the mean acne scar baseline rating of 5.9 (range of 4 to 10) dropped to 3.7 (range of 1 to 7) at 6 months, resulting in a mean acne scar improvement of 2.2 points.

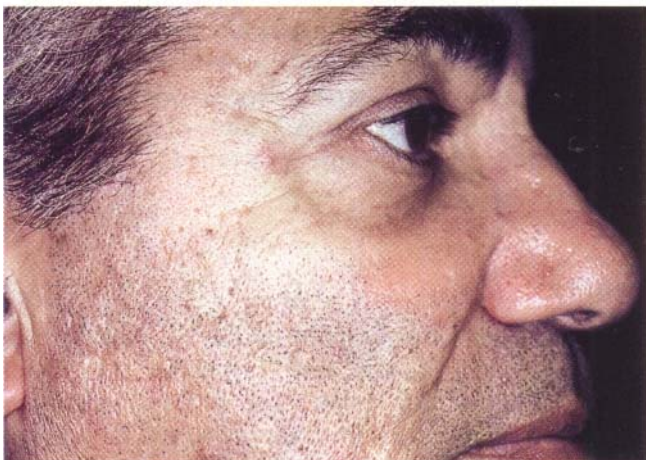Acne scars were rated more severely by subjects than by physician at all intervals (higher mean severity scores of 1.0 points at baseline and 0.3 points at 6 months).

Physician evaluations noted that all subjects had some degree of acne points improvement (more than 3 points = 8%, 1 to 2 points = 92%). Subject evaluations noted that 67% of subjects had acne scar improvement (more than 3 points = 42%, 1 to 2 points = 25%), whereas the remainder had no improvement (0 points = 33%). Worsening acne scar ratings were not reported either by physician or subject assessments.

By acne scar type, subjects with atrophic acne scars (Figures 1 and 2) improved the most (1.7 mean rating points for physician assessments, 2.5 mean rating points for patient assessments). Subjects with a mixed



**Figure 1.** Mixed pattern of facial acne scars at baseline



**Figure 2.** Mixed pattern of facial acne scars 6 months after three treatments with the 1320-nm Nd:YAG laser. Note the improvement of acne scars in the inframalar and temple areas.

pattern of acne scars (Figures 3-6) also improved but to a lesser degree (1.3 mean rating points for physician assessments, 2.0 mean rating points for patient assessments). This trend was not statistically significant (for all differences,  $P > 0.18$ ). There were no complications noted at 6 months.

### Discussion

In understanding how nonablative laser irradiation improves acne scars, it is helpful to compare the histology of the atrophic acne scar to the histology of photoaging before and after nonablative laser remodeling. The photoaging dermis contains diminished collagen, which appears disorganized, irregular, and basophilic in staining.<sup>19</sup> Clinical improvement after nonablative laser irradiation of photoaged skin has been attributed to histologic evidence of new papillary dermal collagen formation. This has been noted in

numerous studies with an intense pulsed light source<sup>20</sup> and the 1320-nm,<sup>15,21,22</sup> 1450-nm,<sup>23</sup> and 1540-nm" lasers. Fournier et al.<sup>18</sup> similarly reported neocollagenesis and also demonstrated a 17% statistically significant increase in dermal thickness with ultrasound imaging of photoaged skin. Therefore, the theory of nonablative laser irradiation in improving acne scars is that because the scars have associated fibrosis and a loss of collagen, they will be improved by laser-induced scar reorganization with organized new collagen fibers.

Nonablative laser treatment of facial acne scars began when Alster and McMeekin<sup>6</sup> demonstrated significant postlaser clinical improvement in erythematous or hypertrophic scars. In their 22 patient study, one to two treatments were delivered at 6 to 7J/cm<sup>2</sup> with the 585-nm, 450- $\mu$ s, flashlamp-pumped pulsed dye laser.

Bernstein et al.'s pilot investigation<sup>12</sup> with a 532nm, 2-ms pulse-duration laser, evaluated "mild-moderate" acne scars in 12 patients and found 54% subjective assessment improvement 3 months after two to four treatments at 4 to 7J/cm<sup>2</sup>. However, photographs demonstrated little or no evidence of improvement, an anomaly attributed to the lack of photograph standardization and lighting.

More recently, Patel and Clement<sup>7</sup> examined saucerized scars irradiated with one treatment at 1.9 to 2.4 j/cm<sup>2</sup> with the 585-nm, 350- $\mu$ s, flashlamp-pumped pulsed dye laser. In their 10-patient study, all patients reported visible cosmetic improvement in the treated areas, whereas surface profilometry showed that the depth of acne scars was reduced by an average of 48%. This impressive reduction in scar depth is consistent with results seen after ablative laser resurfacing.<sup>7,9</sup>

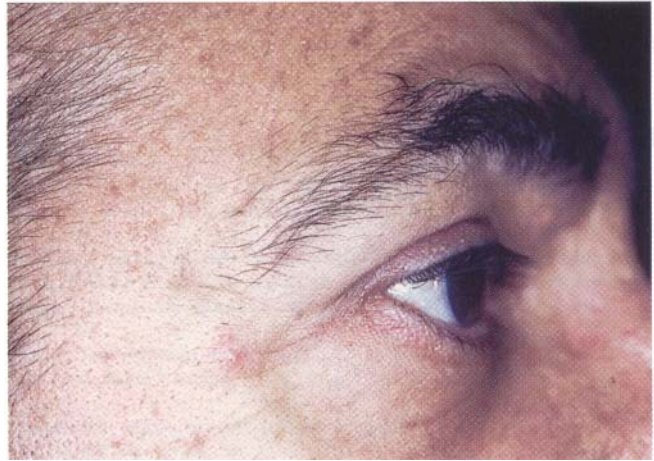
Tanzi and Alster<sup>24</sup> compared the efficacy of the 1320-nm Nd:YAG and the 1450-nm diode lasers in their 20-subject study of the treatment of "mild-moderate" atrophic facial scarring. Acne scar improvement was based on patient satisfaction and in vivo microtopography measurements (PRIMOS Imaging System, GFM, Germany), which paralleled the photographic and histopathologic changes noted. Six months after three laser treatments, the nonablative 1320-nm Nd:YAG and 1450-nm diode lasers each offered mild to moderate clinical improvement.

The salient advantages of the 1320-nm Nd:YAG nonablative laser include its applicability for use in all skin types and its high scattering coefficient. With the laser's long wavelength, laser irradiation scatters throughout the treated dermis after nonspecific absorption by dermal water. Dermal fibroblasts in the papillary and midreticular dermis are then thermally stimulated, leading to collagen remodeling

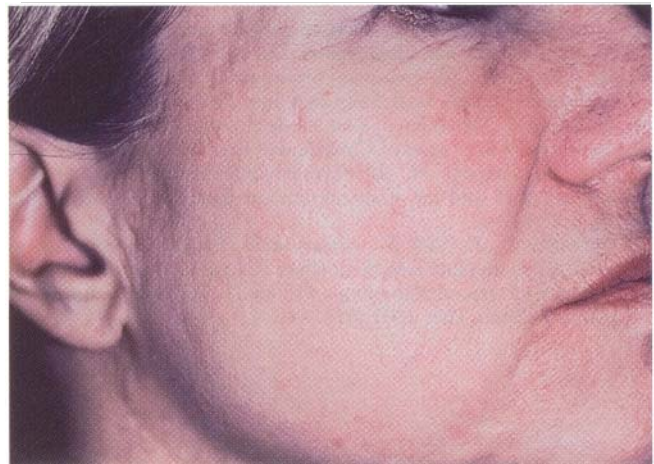and collagen deposition as a natural filling material for acne scars.<sup>25</sup>

Our study demonstrates that the 1320-nm Nd:YAG laser with cryogen spray cooling can safely and effectively improve facial acne scars. Six months after three treatments, the physician and patients observed 1.5 and 2.2 statistically significantly upgraded rating scores, respectively, which translated into mild acne scar correction. For the acne scar patient who may perceive the scarring to be worse than it really is, this level of improvement is meaningful. Furthermore, we observed that acne scars in the concave, inframalar areas of the face, which are particularly distressing to patients,<sup>73</sup> improved dramatically (Figures 1-4).

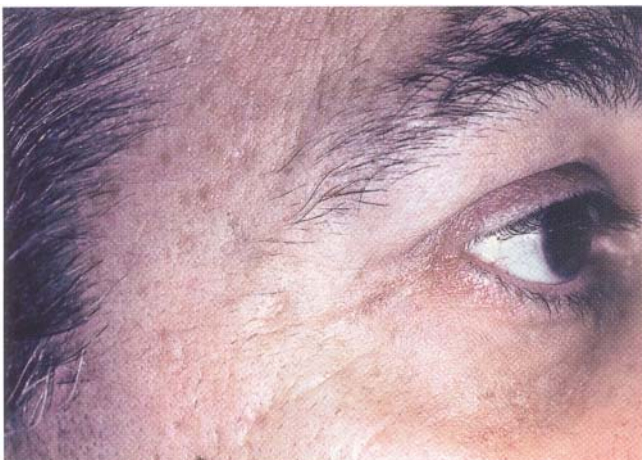With regard to acne scar type, we observed that optimal improvement occurred in patients with atrophic acne scars (Figures 1 and 2). Patients with mixed acne scars also benefited, in part by the improvement in their atrophic scars and in part by the softening of their sclerotic and shallower pitted scars (Figures 3-6). Although our study had a small sample size, overall, we noted that the type of scarring (i.e., atrophic) rather than extent of scarring is the best predictor of response rate to nonablative laser therapy. In conclusion, the 1320-nm Nd:YAG laser can improve the cosmetic appearance of atrophic and a mixed pattern of acne scars in the eyes of the physician and patient. To optimize nonablative laser performance, myriad modalities are available, including scar subcision for atrophic scars, punch excision for icepick scars, and punch elevation, subcision, intradermal fillers, and autologous fat transplantation for boxcar scars.<sup>13,26</sup> By combining these techniques with the laser effect on scars, facial acne scars can be significantly improved.



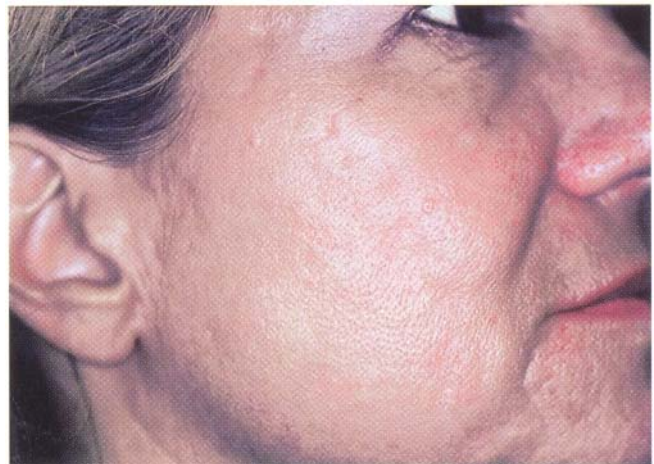**Figure 4.** Deeper atrophic scars and pitted acne scars 6 months after three treatments with the 1320-nm Nd:YAG laser. This close-up view of the temple area demonstrates acne scar improvement. Concurrent periorbital wrinkle reduction is also evident.



**Figure 5.** Atrophic acne scars at baseline.



**Figure 3.** Deeper atrophic scars and pitted acne scars at baseline. This is a close-up view of Figure 2 highlighting the temple area.



**Figure 6.** Atrophic acne scars 6 months after three treatments with the 1320-nm Nd:YAG laser. Atrophic acne scars in the inframalar area are significantly improved.

*Acknowledgment* The authors thank Joan Skurnick, PhD, for her assistance with the statistical analyses.

## References

- Jacob CI, Dover JS, Kaminer MS. Acne scarring: a classification system and review of treatment options. *J Am Acad Dermatol* 2001;45:109-17.
- Cunliffe WJ, Simpson NB. Disorders of the sebaceous glands. In: Champion RH, Burton JL, Burns DA, et al., eds. *Rook/Wilkinson/ Ebling Textbook of Dermatology*. Oxford: Blackwell Science, 1998:1927-84.
- Tsau SS, Dover JS, Arndt KA, et al. Scar management: keloid, hypertrophic, atrophic, and acne scars. *Semin Cutan Med Surg* 2002;21:46-75.
- Walia S, Alster TS. Prolonged clinical and histologic effects from CO2 laser resurfacing of atrophic acne scars. *Dermatol Surg* 1999;25:926-30.
- Lupton JR, Alster TS. Laser scar revision. *Dermatol Clin* 2002;20:55-65.
- Groover 1J, Alster TS. Laser revision of scars and striae. *Dermatol Ther* 2000;13:50-9.
- Lowe N, Lask G, Griffin ME, et al. Skin resurfacing with the ultrapulsed carbon dioxide laser: observation in 100 patients. *Dermatol Surg* 1995;21:1025-9.
- Alster TS, West TB. Resurfacing of atrophic facial scars with a highenergy pulsed carbon dioxide laser. *Dermatol Surg* 1996;22:151-5.
- Tanzi EL, Alster TS. Treatment of atrophic facial acne scars with a dual-mode Er:YAG laser. *Dermatol Surg* 2002;28:551-5.
- Weinstein C. Modulated dual mode erbium/CO2 lasers for the treatment of acne scars. *J Cutan Laser Ther* 1999;1:203-8.
- Patel N, Clement M. Selective nonablative treatment of acne scarring with 585 nm flashlamp pulsed dye laser. *Dermatol Surg* 2002;28:942-5.
- Bernstein EF, Ferreira M, Anderson D. A pilot investigation to subjectively measure treatment effect and side effect profile of nonablative skin remodeling using a 532 nm, 2 ms pulse-duration laser. *J Cosmet Laser Ther* 2001;3:137-41.
- Goodman GJ. Management of post-acne scarring: what are the options for treatment? *Am J Clin Dermatol* 2000;1:3-17.
- Goldberg DJ. Er:YAG resurfacing: what is its role? *Aesthetic Surg J* 1998; 18:255-60.
- Goldberg DJ. Non-ablative subsurface remodeling: clinical and histologic evaluation of a 1320-nm Nd:YAG laser. *J Cutan Laser Ther* 1999;1:153-7.
- Alster TS, McMeekin TO. Improvement of facial acne scars by the 585 nm flashlamp-pumped pulsed dye laser. *J Am Acad Dermatol* 1996;35:79-81.
- Goldberg DJ, Rogachefsky AS, Silapunt S. Non-ablative laser treatment of facial rhytides: a comparison of 1450-nm diode laser treatment with dynamic cooling as opposed to treatment with dynamic cooling alone. *Lasers Surg Med* 2002;30: 79-81.
- Fournier N, Dahan S, Barneon G, et al. Nonablative remodeling. clinical, histologic, ultrasound imaging, and profilometric evaluation of a 1540 nm Er: glass laser. *Dermatol Surg* 2001;27: 799-806.
- Pinnell SR. Cutaneous photodamage, oxidative stress, and topical antioxidant protection. *J Am Acad Dermatol* 2003;48:1-19.
- Goldberg DJ. New collagen formation after dermal remodeling with an intense pulsed light source. *J Cutan Laser Ther* 2000;2: 59-61.
- Trelles MA, Allones I, Luna R. Facial rejuvenation with a nonablative 1320-nm Nd:YAG laser: a preliminary clinical and histologic evaluation. *Dermatol Surg* 2001;27:111-6.
- Trelles MA. Short and long-term follow-up of nonablative 1320-nm Nd:YAG laser facial rejuvenation. *Dermatol Surg* 2001;27: 781-2.
- Lupton JR, Williams CM, Alster TS. Nonablative laser skin resurfacing using a 1450-nm erbium glass laser: a clinical and histologic analysis. *Dermatol Surg* 2002;28:833-5.
- Tanzi EL, Alster TS. Comparison of a 1450-nm diode laser and a 1320-nm Nd:YAG laser in the treatment of atrophic facial scars. *Lasers Surg Med* 2002;14(suppl):28.
- Lask GL, Lee PK, Seyfede M, et al. Nonablative laser treatment of facial rhytids. *SPIT, Proc* 1997;2970:338-49.
- Sawcer D, Lee HR, Lowe NJ. Lasers and adjunctive treatments for facial scars: a review. *J Cutan Laser Ther* 1999;1:77-85.